

Coronary vasomotion after treatment with drug-coated balloons or drug-eluting stents: a prospective, open-label, single-centre randomised trial

Tsutomu Kawai^{1*}, MD; Tetsuya Watanabe¹, MD, PhD; Takahisa Yamada¹, MD, PhD; Takashi Morita¹, MD, PhD; Yoshio Furukawa¹, MD, PhD; Shunsuke Tamaki¹, MD, PhD; Masato Kawasaki¹, MD; Atsushi Kikuchi¹, MD; Masahiro Seo¹, MD; Jun Nakamura¹, MD; Kentaro Tachibana², MAS; Hirota Kida², MAS; Yohei Sotomi³, MD, PhD; Yasushi Sakata³, MD, PhD; Masatake Fukunami¹, MD, PhD

1. Division of Cardiology, Osaka General Medical Center, Osaka, Japan; 2. Clinical Engineering Department, Osaka General Medical Center, Osaka, Japan; 3. Department of Cardiovascular Medicine, Osaka University Graduate School of Medicine, Suita, Japan

This paper also includes supplementary data published online at: <https://eurointervention.pronline.com/doi/10.4244/EIJ-D-21-00636>

KEYWORDS

- drug-eluting balloon
- QCA
- stable angina

Abstract

Background: Although recent studies have reported that drug-coated balloons (DCB) are non-inferior to drug-eluting stents (DES) for the treatment of native coronary arteries in a specific population, there is no available information concerning vasomotion after treatment with DCB.

Aims: The aim of this study was to prospectively compare coronary vasomotion in patients with small coronary artery disease treated with DCB versus DES.

Methods: Forty-two native lesions (2.0-3.0 mm) treated in our institution were randomly assigned to the DCB arm (n=19) or the bioabsorbable polymer everolimus-eluting stents arm (n=23) after successful predilatation. At eight months after treatment, endothelium-dependent and -independent vasomotion was evaluated with intracoronary infusions in incremental doses of acetylcholine (right coronary artery: low dose 5 µg, high dose 50 µg; left coronary artery: low dose 10 µg, high dose 100 µg) and nitroglycerine (200 µg). The mean lumen diameter of the distal segment, beginning 5 mm and ending 15 mm distal to the edge of the treated segment, was quantitatively measured by angiography.

Results: The luminal dimension in the treated segment did not differ between groups at the follow-up angiography. The vasoconstriction after acetylcholine infusion was less pronounced in the DCB arm than in the DES arm (low-dose: 6±13% vs -3±18%, p=0.060; high-dose: -4±17% vs -21±29%, p=0.035). The response to nitroglycerine did not differ between groups (17±13% vs 17±22%, p=0.929).

Conclusions: Vasoconstriction after acetylcholine infusion in the peri-treated region was less pronounced in the DCB arm than in the DES arm, suggesting that endothelial function in treated coronary vessels could be better preserved by DCB than by new-generation DES.

*Corresponding author: Division of Cardiology, Osaka General Medical Center, 3-1-56 Bandai-higashi, Sumiyoshi Ward, Osaka 558-8558, Japan. E-mail: riverclose0604@yahoo.co.jp

Abbreviations

ACh	acetylcholine
DCB	drug-coated balloons
DES	drug-eluting stents
IVUS	intravascular ultrasound
MLD	minimal lumen diameter
NTG	nitroglycerine
PCI	percutaneous coronary intervention
QCA	quantitative coronary angiography
SD	standard deviation
TIMI	Thrombolysis in Myocardial Infarction

Introduction

Drug-eluting stents (DES), particularly new-generation DES, have been widely used for the treatment of coronary artery disease to reduce both the rate of restenosis and the subsequent need for target lesion reintervention. However, several problems related to stent implantation itself remain unresolved, such as stent thrombosis and stent fracture¹. Endothelial dysfunction after stent implantation is another such issue and could lead to serious cardiac events, such as myocardial infarction, fatal arrhythmias, and sudden cardiac death². Although the exact mechanisms underlying endothelial dysfunction after DES implantation remain unknown, possible causes include delays in endothelial repair due to antiproliferative drugs, the direct effects of such drugs or polymers, and mechanical injury by metallic mesh³⁻⁴.

In recent studies, treatment with drug-coated balloons (DCB) for *de novo* coronary artery disease has yielded comparable outcomes to treatment with DES in terms of target lesion revascularisation and major adverse cardiac events⁵⁻⁷. DCB was therefore suggested as an alternative to DES for some lesions. However, despite the effectiveness of DCB for *de novo* coronary artery disease, the physiological responses, especially endothelial function, after treatment with DCB have not been fully investigated. The purpose of this study was to prospectively compare coronary vasomotion in patients treated with DCB or new-generation DES.

Methods

STUDY DESIGN

This study, “The Degree of endothelial Dysfunction caused by treatment of *De novo* coronary lesion with Drug-coated balloon as compared to Drug-eluting stent” (the D5 study) was a prospective, open-label, randomised trial comparing vasomotion in native coronary artery treated with DCB versus new-generation DES. This study was carried out according to the guidelines of the Declaration of Helsinki and was approved by the ethics committee at our institution. All patients in this study provided signed informed consent. The present study was registered at the University Hospital Medical Information Network Clinical Trials Registry in Japan (UMIN000032152).

From April 2018 to March 2020, we enrolled patients suffering from *de novo* lesions scheduled to undergo percutaneous coronary

intervention (PCI) in our institution. The inclusion criteria for patients were age ≥ 20 years and presentation with stable angina or documented silent ischaemia with *de novo* coronary lesions. The inclusion criteria for lesions were a reference vessel diameter of 2.0-3.0 mm (in Japan, DCB is allowed only for in-stent restenosis and small native coronary lesions) and a lesion length of ≤ 25 mm. The exclusion criteria for patients were left ventricular ejection fraction $< 30\%$, acute myocardial infarction within the previous 48 hrs, known renal failure (serum creatinine > 2 mg/dl), known hypersensitivity to or contraindication for the required medication, history of vasospastic angina, or life expectancy < 1 year. The exclusion criteria for lesions were left main lesions, ostial lesions, heavily calcified lesions, thrombotic lesions, or previous stent implantation or another stenotic lesion in the treated vessel. We also excluded patients with restenosis or development of *de novo* significant stenosis ($> 70\%$) at the follow-up angiography.

All study patients received oral aspirin (100 mg/day) and clopidogrel (75 mg/day) for at least five days before PCI. Heparin was administered before and during the procedure to maintain an activated clotting time > 250 s. All lesions were predilated using a regular balloon, a scoring balloon or a cutting balloon with a balloon-to-vessel ratio of 0.8-1.0. If an acceptable angiographic result was obtained (i.e., Thrombolysis in Myocardial Infarction [TIMI] 3 flow, residual stenosis $< 30\%$ and no flow-limiting dissection), patients were randomly assigned in a 1:1 ratio to receive either angioplasty with DCB or implantation of DES according to a computer-generated block randomisation table (random sequences of block sizes between 4 and 8). If a suboptimal result occurred, provisional stenting with DES was performed and the patient was classified into a non-randomised arm. In the DCB arm, the lesion was followed by only one dilation with DCB (SeQuent® Please; B. Braun Melsungen AG, Melsungen, Germany) for ≥ 30 secs. The diameter and length of the DCB were selected with a balloon-to-artery ratio of 1.0 and an overlap of ≥ 2 mm on each edge of the predilation balloon-treated segment, respectively. In the DES arm, stent implantation was performed as standard practice. Post-dilation was left to the discretion of the operator. All DES in the study were bioabsorbable polymer-coated everolimus-eluting stents (SYNERGY™; Boston Scientific, Marlborough, MA, USA). After the procedure, dual antiplatelet therapy was recommended for ≥ 3 months in the DCB arm and ≥ 6 months in both the DES arm and non-randomised arm, followed by aspirin monotherapy indefinitely.

The primary endpoint of this study was endothelial function adjacent to the treated segment by a vasomotion test at the follow-up angiography. Secondary endpoints included angiographic measurements, intravascular ultrasound (IVUS) parameters, and clinical outcomes according to the Academic Research Consortium criteria⁸.

EVALUATION OF ENDOTHELIAL FUNCTION

All patients were scheduled to undergo clinical and angiographic follow-ups at eight months. Endothelial function was evaluated

by an acetylcholine (ACh) vasomotion test at the follow-up angiography⁹. Any medications with potential effects on vasomotor responses, including calcium channel blockers and long-acting nitrates, were withheld for at least 48 hours before the angiography. Endothelium-dependent vasomotor response was assessed by an intracoronary infusion of incremental doses of ACh (5 µg and 50 µg for right coronary artery, 10 µg and 100 µg for left coronary artery; estimated intracoronary concentrations of 3.4×10^{-7} and 3.4×10^{-6} mol/l, respectively) for 1 minute. Subsequently, an intracoronary bolus injection of nitroglycerine (NTG, 200 µg) was administered to assess the endothelium-independent vasomotor response. A 3 minute period was allowed to elapse between each drug infusion. Throughout the procedures, the heart rate, the systemic blood pressure, and the electrocardiogram were continuously monitored.

During the ACh vasomotion test, projection of the coronary angiography (CAG) was fixed as the most suitable to show the artery of interest, without overlapping side branches and with less foreshortening. Offline quantitative coronary angiography (QCA) was performed using coronary angiography analysis software (CAAS version 5.9; Pie Medical Imaging, Maastricht, the Netherlands). Calibration of the system was based on dimensions of the guiding catheter. The mean lumen diameter of the distal segment, beginning 5 mm and ending 15 mm distal to the end of the treated segment, was measured to evaluate vasomotor responses and was the primary endpoint of this study¹⁰. The definition of each segment is shown in **Figure 1**. The same segments were identified by anatomical landmarks and were assessed at the baseline, after each dose of ACh and after the NTG bolus. Changes in the coronary diameter, in response to the ACh and NTG coronary infusions, were expressed as percentage changes in mean lumen diameter versus baseline angiograms. Measurements were performed by two independent, experienced investigators. Intra- and inter-observer variability for QCA were assessed in the same recordings of 10 randomly selected patients by intraclass correlation coefficients (ICC) and showed excellent agreements (consistency ICC 0.973, 95% CI: 0.950-0.986 and ICC 0.952, 95% CI: 0.915-0.975, respectively).

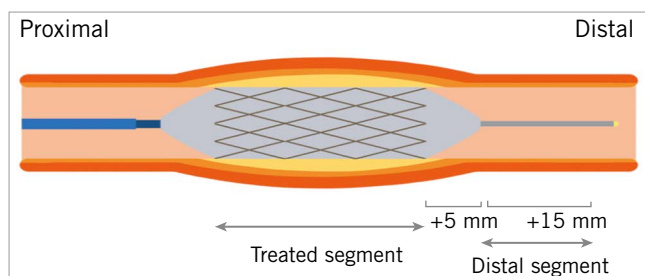


Figure 1. Definition of each segment. A representation of the segment treated with the drug-coated balloon or drug-eluting stent. The distal segment begins 5 mm and ends 15 mm distal to the end of the treated segment.

INTRAVASCULAR ULTRASOUND

Before the pre- and post-procedure image acquisitions, 200 µg of intracoronary NTG was routinely administered. At the eight-month follow-up, an IVUS examination was performed after the ACh vasomotion test. The IVUS imaging was performed using a high-definition 60 MHz IVUS system (AltaView™; Terumo Corp., Tokyo, Japan) with an automatic pullback device at 3 mm/s. Offline analyses were performed using an IVUS imaging system (VISICUBE; Terumo Corp., Tokyo, Japan). The geometric characteristics of the treated segments were analysed, and lesions were confirmed using identical landmarks such as side branches, calcification, pericardium, vein, and plaque shape.

Geometric quantitative IVUS analyses were performed according to the criteria of the clinical expert consensus document¹¹. The leading edge of the lumen and the external elastic membrane were traced using manual planimetry and the plaque area was defined as the area between these leading edges. As cross-sectional images were obtained at 1.0 mm intervals, the total plaque and lumen volume were calculated using the Simpson rule as the mean plaque and lumen area multiplied by the pullback distance in millimetres. IVUS measurements were performed by an independent examiner who was blinded to the clinical characteristics of participants.

STATISTICAL ANALYSIS

Based on the results of previous studies^{4,12}, we expected that treatment with DCB would achieve a $5 \pm 5\%$ reduction in coronary vasospastic response to ACh compared to treatment with DES. The assumption used for power calculations required a sample size of 16 patients per each group to provide 80% power (assuming a standard deviation [SD] of 5%) to detect a 5% difference with a 5% type I error rate for two-sided testing. Given a restenosis rate of 5-10% and some dropouts, the total sample size required is 50 (25 in each arm). Continuous variables are expressed as mean \pm SD for values showing a normal distribution, or as medians and interquartile ranges for values showing anormal distributions. Categorical data are presented as absolute values and/or frequencies. Baseline group characteristics were compared using a t-test for continuous variables showing a normal distribution or Mann-Whitney's U-test for continuous variables showing anormal distributions, and the chi-square or Fisher's exact test for categorical variables. Changes in vessel diameter in response to drug infusions among groups were compared with an unpaired Student's t-test, and interactions between groups were tested by two-way repeated measures analysis of variance (ANOVA). Statistical significance was set at the level of $p < 0.05$. All the statistical analyses were carried out using EZR version 1.53 (Saitama Medical Center, Jichi Medical University, Saitama, Japan), and the graphical user interface for R (The R Foundation for Statistical Computing, Vienna, Austria)¹³.

Results

POPULATION AND BASELINE CHARACTERISTICS

From April 2018 to March 2020, 46 patients who were eligible based on the inclusion criteria were enrolled in this study. Nineteen

patients were assigned to the DCB arm, twenty-three patients to the DES arm, and four patients to the non-randomised arm because of suboptimal results after predilation. A follow-up angiography was not performed for one patient in the DES arm because of worsening renal function. Therefore, a total of 41 patients (DCB arm, 19 patients; DES arm, 22 patients) underwent angiographic follow-ups. All patients, except one patient in the DES arm who showed a new, significant stenosis in a non-treated vessel, subsequently received an ACh vasomotion test (Figure 2). No major adverse cardiac events including death, target lesion revascularisation, and myocardial infarction, occurred during the follow-up.

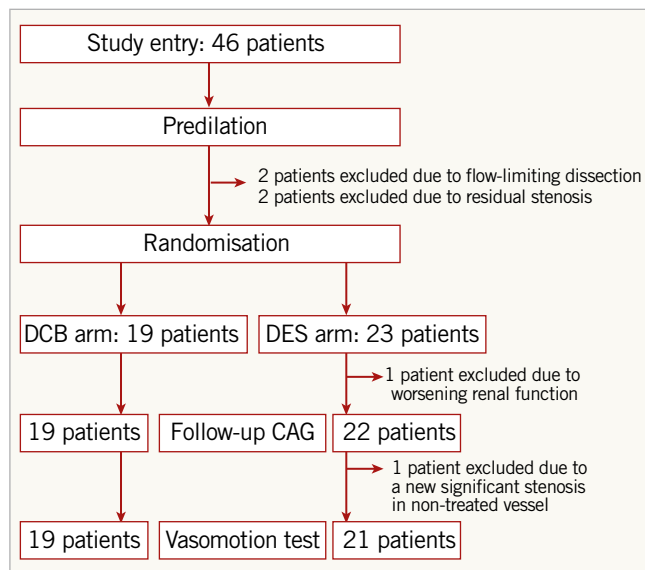


Figure 2. Study flow. CAG: coronary angiography; DCB: drug-coated balloon; DES: drug-eluting stent.

The baseline patient characteristics are summarised in Table 1. No significant differences in the baseline patient characteristics were evident between the groups. Table 2 summarises lesion and procedural characteristics. The patients in the DCB arm were treated with lower pressure than patients in the DES arm due to differences in nominal pressure between each device. No other significant differences in baseline lesion and procedural characteristics were seen between the groups.

ANGIOGRAPHIC RESULTS FOR THE TREATED SEGMENT

Serial changes in QCA measurements from the treated segments are summarised in Table 3. Measurements showed a slightly higher % diameter stenosis at pre-procedure in the DCB arm compared to the DES arm. After the procedure, lesions treated with DCB showed lower acute gain, therefore lower minimal lumen diameter (MLD) and higher % diameter stenosis than lesions treated with DES. At the follow-up, QCA measurements showed lower late lumen loss in the DCB arm compared to the DES arm. As a result, differences in MLD and % diameter stenosis between groups disappeared.

Table 1. Clinical characteristics in study patients.

		DCB n=19	DES n=23	p-value
Age, years		69±8	73±8	0.176
Male		15 (79)	17 (74)	0.711
BMI, kg/m ²		25±4	24±4	0.237
CCS class		1 (0-3)	1 (0-2)	0.540
Clinical presentation	Stable angina pectoris	12 (63)	18 (78)	0.499
	Positive functional stress test	7 (37)	5 (22)	
Risk factors	Hypertension	17 (89)	21 (91)	0.845
	Diabetes mellitus	5 (26)	8 (35)	0.566
	Dyslipidaemia	15 (79)	19 (83)	0.770
	Smoking	10 (53)	12 (52)	0.977
Prior myocardial infarction		2 (11)	5 (22)	0.344
Prior PCI		10 (53)	10 (43)	0.566
Prior CABG		1 (5)	0 (0)	0.277
Medication	ACEIs or ARBs	9 (47)	13 (57)	0.566
	β-blockers	7 (37)	7 (30)	0.670
	Statins	16 (84)	16 (70)	0.279
	Ca blockers	10 (53)	13 (57)	0.807
	Nitrates	4 (21)	4 (17)	0.770
	Dual antiplatelets	19 (100)	23 (100)	>0.99
Laboratory data	Creatinine, mg/dl	0.8 (0.6-1.8)	0.9 (0.5-1.2)	0.610
	LDL cholesterol, mg/dl	88±20	88±25	0.991
	HbA1c, %	6.1±0.7	6.6±1.1	0.059
LV ejection fraction, %		67±7	66±10	0.713

Values are mean±SD, the median (25-75 percentiles) or n (%). ACEI: angiotensin-converting enzyme inhibitor; ARB: angiotensin II receptor blocker; BMI: body mass index; CABG: coronary artery bypass grafting; CCS: Canadian Cardiovascular Society; DCB: drug-coated balloon; DES: drug-eluting stent; LDL: low-density lipoprotein; LV: left ventricular; PCI: percutaneous coronary intervention

Table 2. Lesion and procedural characteristics in study patients.

		DCB n=19	DES n=23	p-value
Target vessel	Left anterior descending/diagonal	8 (42)	4 (17)	0.074
	Circumflex/marginal branch	5 (26)	14 (61)	
	Right coronary artery	6 (32)	5 (22)	
AHA type B2/C		5 (26)	8 (35)	0.257
Predilation		19 (100)	23 (100)	>0.99
Scoring balloon/cutting balloon		18 (95)	21 (91)	0.676
Predilation balloon diameter, mm		2.4±0.4	2.4±0.3	0.472
Predilation balloon pressure, atm		12±2.8	10±3.0	0.202
Device diameter, mm		2.6±0.4	2.4±0.3	0.118
Device length, mm		19±4.6	17±4.8	0.066
Device pressure, atm		7.7±2.2	13±3.0	<0.001

Values are mean±SD or n (%). AHA: American Heart Association; DCB: drug-coated balloon; DES: drug-eluting stent

Table 3. Serial changes of angiographic measurements in treated segments.

	DCB n=19	DES n=22	p-value
Pre-procedure			
Reference vessel diameter, mm	2.29±0.49	2.08±0.43	0.160
Minimal lumen diameter, mm	0.75±0.33	0.80±0.21	0.467
Diameter stenosis, %	68±12	60±9	0.025
Lesion length, mm	11.8±4.6	11.3±5.5	0.751
Post-procedure			
Minimal lumen diameter, mm	1.70±0.29	2.20±0.42	<0.001
Diameter stenosis, %	24±15	3±13	<0.001
Acute gain, mm	0.95±0.31	1.39±0.39	<0.001
Follow-up			
Minimal lumen diameter, mm	1.78±0.64	1.83±0.63	0.772
Diameter stenosis, %	20±22	15±21	0.405
Late lumen loss, mm	-0.07±0.43	0.37±0.40	0.002
Binary stenosis	3 (16)	1 (5)	0.321
Values are mean±SD or n (%). DCB: drug-coated balloon; DES: drug-eluting stent			

ENDOTHELIAL FUNCTION ANALYSIS

Representative cases of each arm are shown in **Central illustration A**. **Central illustrations B and C** show percentage changes in mean lumen diameter for the evaluation of vasomotion in response to ACh and NTG. In the distal segment (**Central illustration B**), vasoconstriction after ACh infusion was less pronounced in the DCB arm than in the DES arm (low-dose: 6±13% vs -3±18%, p=0.060; high-dose: -4±17% vs -21±29%, p=0.035), for between-group differences of 9% (95% CI: 0 to 20) after low-dose ACh infusion and 17% (95% CI: 1 to 32) after high-dose ACh infusion. The response to NTG did not differ between groups (17±13% vs 17±22%, p=0.929). In addition, significant interaction of the two groups in the vasomotion test was identified (p=0.037, ANOVA). In contrast, no significant difference between groups was seen in vasoconstriction of the treated segment (**Central illustration C**, p=0.227, ANOVA). Serial changes in lumen diameter in individual cases are shown in **Supplementary Figure 1**.

Absolute values of the mean lumen diameter in response to ACh and NTG showed consistent results (**Table 4**). In the distal segment, the mean lumen diameter in response to ACh was significantly greater in the DCB arm than in the DES arm. On the other hand, in the treated segment, no differences between groups were seen in the lumen size in response to ACh and NTG. Scatter plots comparing the control mean lumen diameter and the mean lumen diameter following a high-dose ACh infusion in the distal segment are shown in **Supplementary Figure 2**.

IVUS RESULT FOR TREATED SEGMENT

Procedural and follow-up IVUS measurements are summarised in **Supplementary Table 1**. IVUS images were analysable

Table 4. Serial changes in mean lumen diameter in response to ACh and NTG infusion.

	DCB n=19	DES n=21	p-value
Distal segment			
Control, mm	1.78±0.42	1.58±0.45	0.149
Low-dose ACh, mm	1.89±0.48	1.51±0.44	0.014
High-dose ACh, mm	1.72±0.52	1.27±0.54	0.011
NTG, mm	2.07±0.37	1.78±0.36	0.026
Treated segment			
Control, mm	1.97±0.42	2.15±0.51	0.233
Low-dose ACh, mm	2.03±0.37	2.17±0.44	0.304
High-dose ACh, mm	1.95±0.40	2.08±0.65	0.427
NTG, mm	2.19±0.39	2.19±0.41	0.963
Values are mean±SD. ACh: acetylcholine; DCB: drug-coated balloon; DES: drug-eluting stent; NTG: nitroglycerine			

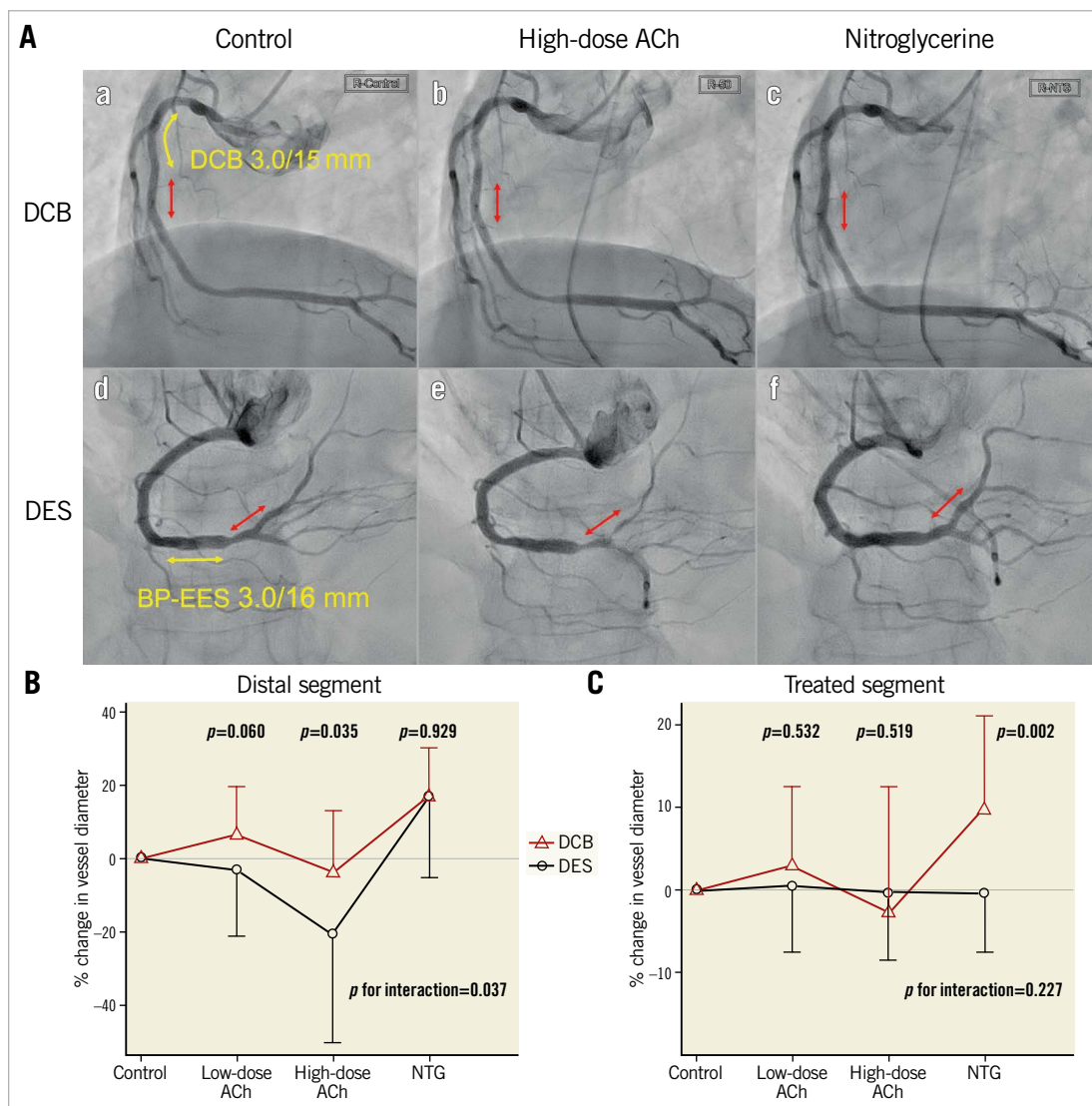
for 34 patients (DCB, n=17/19 [89%]; DES, n=17/22 [77%]). Measurements showed a larger plaque area and minimal lumen area in the DCB arm than in the DES arm. No significant differences were found in the mean lumen area at the baseline. Lesions treated in the DCB arm displayed lower acute gain after the procedure, but lower late lumen area loss at the follow-up than the DES arm. These results were consistent with the angiographic results.

Discussion

The current study demonstrated that endothelial vasomotor reactivities after treatment with DCB were better preserved than with DES. In terms of angiographic results in the treated segment, treatment with DCB for *de novo* coronary lesions could be comparable to treatment with DES at the follow-up period, consistent with previous reports⁵⁻⁷. To the best of our knowledge, this is the first trial to investigate endothelial vasoreactivity after DCB treatment, finding better preservation of endothelial vasomotor activity after treatment with DCB compared to new-generation DES.

In patients with coronary artery disease, DES dramatically reduces both the rate of restenosis and the subsequent need for target lesion reintervention. However, many studies have reported endothelial dysfunction after stent implantation. Endothelial dysfunction was first reported after bare metal stent implantation⁴, and multiple trials have since demonstrated severe endothelial dysfunction after first-generation DES implantation^{14,15}. More recent studies have shown that new-generation DES also induced endothelial dysfunction, although to a lesser degree than first-generation DES^{9,10,12}. On the other hand, an *in vitro* study using porcine coronary artery showed that endothelium-related vasodilation was better preserved in vessels treated with DCB than in vessels treated with DES implantation¹⁶. However, coronary endothelial function after treatment with DCB in clinical practice has not been fully explored.

Although the pathophysiology of the endothelial dysfunction remains unknown, several possible causes have been suggested so far, including delayed endothelial repair, direct effects



Central illustration. Comparison of vasomotion after DCB versus DES. A. Representative cases of the vasomotion test eight months after treatment with drug-coated balloons (DCB) and drug-eluting stents (DES). Aa and Ad show control coronary angiograms. Ab and Ae show angiograms after infusion of high-dose acetylcholine (ACh). Ac and Af show angiograms after infusion of nitroglycerine (NTG). The red arrows indicate distal segments, as the regions of interest in vasomotion studies. The yellow arrows indicate treated segments. Vasospasm occurred in the distal segment in a patient with DES, but not with DCB. B, C. Percentage change in vessel diameter in response to ACh and NTG in the distal segment and treated segment. Mean values with standard deviation as error bar are shown. P values for interaction indicate differences between the randomised groups and serial drug infusions. BP-EES, bioabsorbable polymer-coated everolimus-eluting stent

of antiproliferative drugs or polymers, and mechanical injury by metallic mesh^{3-4,17}.

All DES used in the present study were SYNERGY™. This bioabsorbable, polymer-coated, thin-strut DES has shown excellent endothelial stent coverage in previous *in vitro* and *in vivo* studies¹⁸⁻²⁰. However, the function and maturation of newly developed endothelial cells after new-generation DES implantation have not been well studied. A study using optical frequency domain imaging reported dissimilar properties of the neointima after implantation of a bioresorbable scaffold and DES²¹. The stent might be covered with new endothelium when treated with DES, but the original endothelium remains buried under the stent. On the other

hand, when treated with DCB, original endothelial cells may remain in the treated vessels because of the absence of a metallic barrier. The functional difference between the newly developed and original endothelium might lead to the results shown in the present study.

In this study, the direct influence of antiproliferative drugs and polymers might be negligible. After the release of the paclitaxel from SeQuent® Please and its adsorption by the vessel wall, the concentration of paclitaxel in the vessel wall declines to almost zero within 24 hours²². On the other hand, after implantation of the SYNERGY™ stents, everolimus is released for 90 days. In terms of polymers, SYNERGY™ stents also have an abluminal

poly-lactide-co-glycolide polymer that is resorbed within four months despite of the ensured coating integrity²³⁻²⁵. Therefore, at follow-up angiography eight months after the initial procedure, the remaining antiproliferative drugs and polymer should exert minimal influence on endothelial function.

Mechanical injury by metallic mesh could affect the vasomotion of adjacent arterial segments. A previous study reported that more severe endothelial dysfunction was observed in the long-term after stenting as compared to plain ballooning or directional atherectomy⁴. Another study showed that the strong, permanent passive stretching of the endothelial and muscular layers by stenting elicited hypersensitivity of the adjacent arterial segments to endothelin, probably through endothelin-related contraction due to interactions with G protein-coupled receptors, or the production of asymmetric dimethylarginine increasing vascular resistance¹⁶. Such observations could provide one explanation for the impairment of endothelial vasomotor reactivity in the DES arm.

Several studies have reported that DCB for *de novo* coronary lesions was associated with non-inferior clinical outcomes, even when compared to new-generation DES⁵⁻⁷. In terms of angiographic results, treatment with DCB tended to be associated with smaller lumen diameter and acute gain, but also with lower late lumen loss, and non-inferior results to DES were achieved at the angiographic follow-up^{5,26}. On this point, the present results were consistent with findings from those studies. More interestingly, according to a recent meta-analysis of DCB for *de novo* coronary lesions, the incidence of all-cause mortality and myocardial infarction was lower with DCB treatment, despite the similar or slightly worse angiographic results²⁷. This paradoxical finding may derive from the difference between presence and absence of permanent implants. The vasoconstriction provoked after stent implantation could result in blood flow reduction and exacerbation of nonlaminar flow within the stented vessel. These likely link to increases in inflammatory and thrombotic risks and lead to stent-related adverse events^{2,28,29}. On the other hand, DCB for *de novo* coronary lesions can better preserve the physiological functioning of vessels. Therefore, a stentless strategy with DCB may be a safer treatment for a particular subset of *de novo* coronary lesions.

Limitations

First, the baseline endothelial function was not investigated. The initial endothelial function test could not be applied, because all study patients had significant coronary lesions and the safety of the ACh vasomotion test was a concern. In addition, several lesion characteristics, especially in IVUS examination, were different between groups. It is reported that epicardial spasm is more often located in the distal small coronary segments. Therefore, there was a concern regarding the influence of vessel size on vasoconstriction. However, in this present study, there were no significant correlations between percentage changes in mean lumen diameter to high-dose ACh in the distal segment and vessel size, such as the mean diameter of the distal segment in QCA ($r^2=0.274$, $p=0.087$) and the mean vessel area of

the treated segment measured with IVUS ($r^2=0.179$, $p=0.297$). Second, after randomisation, one patient assigned to the DES arm was excluded before angiography and another patient could not receive the vasomotion test. However, the baseline lesion and procedural characteristics were still well balanced among the two groups in the analysis of patients who could receive angiography or vasomotion test. In addition, similar tendencies could be seen in serial changes in QCA measurements of treated lesions when we limited the analysis to patients who could receive vasomotion tests. Third, the present study investigated only patients with small coronary artery diseases. Therefore, the applicability of the current findings may be limited in larger (≥ 3.0 mm reference diameter) coronary artery diseases. Fourth, racial differences might have influenced the present results. Asian populations exhibit a higher degree of coronary vasoconstriction in response to ACh infusion than Caucasians³⁰. Fifth, the rate of scoring/cutting balloon use is remarkably high. In Japan, the scoring/cutting balloon for lesion preparation is popular. However, this may not reflect the practice outside of Japan. Finally, the present study was a single-centre study with a small sample size, so the results should be considered preliminary. In addition, the real-world clinical implications of the differences in endothelial function between each device remain unclear. A larger number of subjects and a longer follow-up of clinical outcomes are crucial to confirm the efficacy of DCB.

Conclusions

This study provides evidence that treatment with DCB for *de novo* coronary lesion could be comparable to treatment with DES in terms of the angiographic results, and that vasoconstriction after ACh infusion in the peri-treated region was less pronounced in lesions treated with DCB than in those treated with DES. This suggests that the endothelial function of coronary vessels treated with DCB may be better preserved than that of vessels treated with new-generation DES.

Impact on daily practice

Endothelial dysfunction after PCI could lead to serious cardiac events, such as myocardial infarction, fatal arrhythmia, or sudden cardiac death. The present study is the first to reveal that endothelial function is better preserved in coronary vessels treated with DCB than with new-generation DES. The present results suggest that DCB for *de novo* coronary lesions can preserve the physiological functioning of vessels better than new-generation DES, which may be a beneficial effect of the "leave nothing behind" concept of DCB.

Acknowledgements

The authors thank Daisuke Sakamoto from Osaka General Medical Center (Osaka, Japan) for his technical assistance, and Kanako Ueda, Yumiko Sugie, and Junko Tsugawa from Osaka General Medical Center (Osaka, Japan) for their secretarial assistance.

Funding

This study was partially funded by Osaka Heart Club (Osaka, Japan), which has no relationship with the industry. The funder supported the conduct of the study.

Conflict of interest statement

Y. Sotomi received research grants and speaker honoraria from Abbott Vascular Japan, Boston Scientific Japan, Terumo, Japan Lifeline, Biosensors, Medtronic, Daiichi-Sankyo, Bayer, Boehringer Ingelheim, and Bristol-Myers Squibb and is an endowed chair funded by Terumo, Asahi Intecc, Nipro, and Shimadzu Corporation. The other authors have no conflicts of interest to declare.

References

- Philip F, Stewart S, Southard JA. Very late stent thrombosis with second generation drug eluting stents compared to bare metal stents: network meta-analysis of randomized primary percutaneous coronary intervention trials. *Catheter Cardiovasc Interv*. 2016;88:38-48.
- Brott BC, Anayiotos AS, Chapman GD, Anderson PG, Hillegass WB. Severe, diffuse coronary artery spasm after drug-eluting stent placement. *J Invasive Cardiol*. 2006;18:584-92.
- Lüscher TF, Steffel J, Eberli FR, Joner M, Nakazawa G, Tanner FC, Virmani R. Drug-eluting stent and coronary thrombosis: biological mechanisms and clinical implications. *Circulation*. 2007;115:1051-8.
- Caramori PR, Lima VC, Seidelin PH, Newton GE, Parker JD, Adelman AG. Long-term endothelial dysfunction after coronary artery stenting. *J Am Coll Cardiol*. 1999;34:1675-9.
- Nishiyama N, Komatsu T, Kuroyanagi T, Fujikake A, Komatsu S, Nakamura H, Yamada K, Nakahara S, Kobayashi S, Taguchi I. Clinical value of drug-coated balloon angioplasty for de novo lesions in patients with coronary artery disease. *Int J Cardiol*. 2016;222:113-8.
- Jeger RV, Farah A, Ohlow MA, Mangner N, Möbius-Winkler S, Leibundgut G, Weilenmann D, Wöhrle J, Richter S, Schreiber M, Mahfoud F, Linke A, Stephan FP, Mueller C, Rickenbacher P, Coslovsky M, Gilgen N, Osswald S, Kaiser C, Scheller B; BASKET-SMALL 2 Investigators. Drug-coated balloons for small coronary artery disease (BASKET-SMALL 2): an open-label randomised non-inferiority trial. *Lancet*. 2018;392:849-56.
- Scheller B, Ohlow MA, Ewen S, Kische S, Rudolph TK, Clever YP, Wagner A, Richter S, El-Garhy M, Böhm M, Degenhardt R, Mahfoud F, Lauer B. Bare metal or drug-eluting stent versus drug-coated balloon in non-ST-elevation myocardial infarction: the randomised PEPCAD NSTEMI trial. *EuroIntervention*. 2020;15:1527-33.
- Cutlip DE, Windecker S, Mehran R, Boam A, Cohen DJ, van Es GA, Steg PG, Morel MA, Mauri L, Vranckx P, McFadden E, Lansky A, Hamon M, Krucoff MW, Serruys PW; Academic Research Consortium. Clinical end points in coronary stent trials: a case for standardized definitions. *Circulation*. 2007;115:2344-51.
- Kim JW, Seo HS, Park JH, Na JO, Choi CU, Lim HE, Kim EJ, Rha SW, Park CG, Oh DJ. A prospective, randomized, 6-month comparison of the coronary vasomotor response associated with a zotarolimus- versus a sirolimus-eluting stent: differential recovery of coronary endothelial dysfunction. *J Am Coll Cardiol*. 2009;53:1653-9.
- Hamilos MI, Ostojic M, Beleslin B, Sagic D, Mangovski L, Stojkovic S, Nedeljkovic M, Orlic D, Milosavljevic B, Topic D, Karanovic N, Wijns W; NOBORI CORE Investigators. Differential effects of drug-eluting stents on local endothelium-dependent coronary vasomotion. *J Am Coll Cardiol*. 2008;51:2123-9.
- Mintz GS, Nissen SE, Anderson WD, Bailey SR, Erbel R, Fitzgerald PJ, Pinto FJ, Rosenfield K, Siegel RJ, Tuzcu EM, Yock PG. American College of Cardiology clinical expert consensus document on standards for acquisition, measurement and reporting of intravascular ultrasound studies (IVUS). A report of the American College of Cardiology Task Force on Clinical Expert Consensus Documents. *J Am Coll Cardiol*. 2001;37:1478-92.
- Roura G, Homs S, Ferreira JL, Gomez-Lara J, Romaguera R, Teruel L, Sanchez-Elvira G, Ariza-Solé A, Gómez-Hospital JA, Cequier Á. Preserved endothelial vasomotor function after everolimus-eluting stent implantation. *EuroIntervention*. 2015;11:643-9.
- Kanda Y. Investigation of the freely available easy-to-use software 'EZR' for medical statistics. *Bone Marrow Transplantation*. 2013;48:452-8.

- Togni M, Windecker S, Cocchia R, Wenaweser P, Cook S, Billinger M, Meier B, Hess OM. Sirolimus-eluting stents associated with paradoxical coronary vasoconstriction. *J Am Coll Cardiol*. 2005;46:231-6.
- Kim JW, Suh SY, Choi CU, Na JO, Kim EJ, Rha SW, Park CG, Seo HS, Oh DJ. Six-month comparison of coronary endothelial dysfunction associated with sirolimus-eluting stent versus Paclitaxel-eluting stent. *JACC Cardiovasc Interv*. 2008;1:65-71.
- Plass CA, Sabydusheva-Litschauer I, Bernhart A, Samaha E, Petnehazy O, Szentirmai E, Petrási Z, Lamin V, Pavo N, Nyolczas N, Jakab A, Murlasits Z, Bergler-Klein J, Maurer G, Gyöngyösi M. Time course of endothelium-dependent and -independent coronary vasomotor response to coronary balloons and stents. Comparison of plain and drug-eluting balloons and stents. *JACC Cardiovasc Interv*. 2012;5:741-51.
- Tamaru H, Fujii K, Otsuji S, Takiuchi S, Hasegawa K, Ishibuchi K, Ishii R, Yamamoto W, Nakabayashi S, Higashino Y. Short- and mid-term influence of drug-coated stent implantation on structural and functional vascular healing response: An optical coherence tomography and acetylcholine testing study. *Catheter Cardiovasc Interv*. 2021;97:E186-93.
- Wilson GJ, Huibregtse BA, Pennington DE, Dawkins KD. Comparison of the SYNERGY with the PROMUS (XIENCE V) and bare metal and polymer-only Element control stents in porcine coronary arteries. *EuroIntervention*. 2012;8:250-7.
- Nakazawa G, Torii S, Ijichi T, Nagamatsu H, Ohno Y, Kurata F, Yoshikawa A, Nakano M, Shinozaki N, Yoshimachi F, Ikari Y. Comparison of Vascular Responses Following New-Generation Biodegradable and Durable Polymer-Based Drug-Eluting Stent Implantation in an Atherosclerotic Rabbit Iliac Artery Model. *J Am Heart Assoc*. 2016;5:e003803.
- Vesga B, Hernandez H, Moncada M, Gasior P, Higuera S, Dager A, Arana C, Delgado JA, Gêneroux P, Maehara A, Granada JF. Three-month evaluation of strut healing using a novel optical coherence tomography analytical method following bioresorbable polymer everolimus-eluting stent implantation in humans: the TIMELESS study. *Coron Artery Dis*. 2017;28:126-34.
- Sotomi Y, Onuma Y, Liu S, Asano T, Eggermont J, Katagiri Y, Cavalcante R, de Winter RJ, Wykrzykowska JJ, Brugaletta S, Räber L, Sabaté M, Windecker S, Dijkstra J, Serruys PW. Quality difference of neointima following the implantation of everolimus-eluting bioresorbable scaffolds and metallic stents in patients with ST-elevation myocardial infarction: quantitative assessments by light intensity, light attenuation, and backscatter on optical coherence tomography in the TROFI II trial. *EuroIntervention*. 2018;14:678-85.
- Axel DI, Kunert W, Göggelmann C, Oberhoff M, Herdeg C, Küttner A, Wild DH, Brehm BR, Riessen R, Köveker G, Karsch KR. Paclitaxel inhibits arterial smooth muscle cell proliferation and migration in vitro and in vivo using local drug delivery. *Circulation*. 1997;96:636-45.
- Meredith IT, Verheye S, Dubois CL, Dens J, Fajadet J, Carrié D, Walsh S, Oldroyd KG, Varenne O, El-Jack S, Moreno R, Joshi AA, Allocco DJ, Dawkins KD. Primary endpoint results of the EVOLVE trial: a randomized evaluation of a novel bioabsorbable polymer-coated, everolimus-eluting coronary stent. *J Am Coll Cardiol*. 2012;59:1362-70.
- Wilson GJ, Marks A, Berg KJ, Eppihimer M, Sushkova N, Hawley SP, Robertson KA, Knapp D, Pennington DE, Chen YL, Foss A, Huibregtse B, Dawkins KD. The SYNERGY biodegradable polymer everolimus eluting coronary stent: Porcine vascular compatibility and polymer safety study. *Catheter Cardiovasc Interv*. 2015;86:E247-57.
- Watanabe T, Fujita M, Awata M, Iida O, Okamoto S, Ishihara T, Uematsu M. Integrity of stent polymer layer after drug-eluting stent implantation: in vivo comparison of sirolimus-, paclitaxel-, zotarolimus- and everolimus-eluting stents. *Cardiovasc Interv Ther*. 2014;29:4-10.
- Cortese B, Di Palma G, Guimaraes MG, Piraino D, Orrego PS, Buccheri D, Rivero F, Perotto A, Zambelli G, Alfonso F. Drug-Coated Balloon Versus Drug-Eluting Stent for Small Coronary Vessel Disease: PICCOLETO II Randomized Clinical Trial. *JACC Cardiovasc Interv*. 2020;13:2840-9.
- Elgendy IY, Gad MM, Elgendy AY, Mahmoud A, Mahmoud AN, Cuesta J, Rivero F, Alfonso F. Clinical and Angiographic Outcomes With Drug-Coated Balloons for De Novo Coronary Lesions: A Meta-Analysis of Randomized Clinical Trials. *J Am Heart Assoc*. 2020;9:e016224.
- Pendyala LK, Yin X, Li J, Chen JP, Chronos N, Hou D. The first-generation drug-eluting stents and coronary endothelial dysfunction. *JACC Cardiovasc Interv*. 2009;2:1169-77.
- Schächinger V, Britten MB, Zeiher AM. Prognostic impact of coronary vasodilator dysfunction on adverse long-term outcome of coronary heart disease. *Circulation*. 2000;101:1899-906.
- Pristipino C, Beltrame JF, Finocchiaro ML, Hattori R, Fujita M, Mongiardo R, Cianflone D, Sanna T, Sasayama S, Maseri A. Major racial differences in coronary constrictor response between Japanese and Caucasians with recent myocardial infarction. *Circulation*. 2000;101:1102-8.

Supplementary data

Supplementary Table 1. Serial changes of IVUS measurements in treated segments.

Supplementary Figure 1. Percentage changes in lumen diameter in individual cases.

Supplementary Figure 2. Scatter plots and best fit lines of linear regression comparing the control mean lumen diameter and the

mean lumen diameter following high-dose ACh infusion in the distal segment.

The supplementary data are published online at:

<https://eurointervention.pronline.com/>

[doi/10.4244/EIJ-D-21-00636](https://doi.org/10.4244/EIJ-D-21-00636)



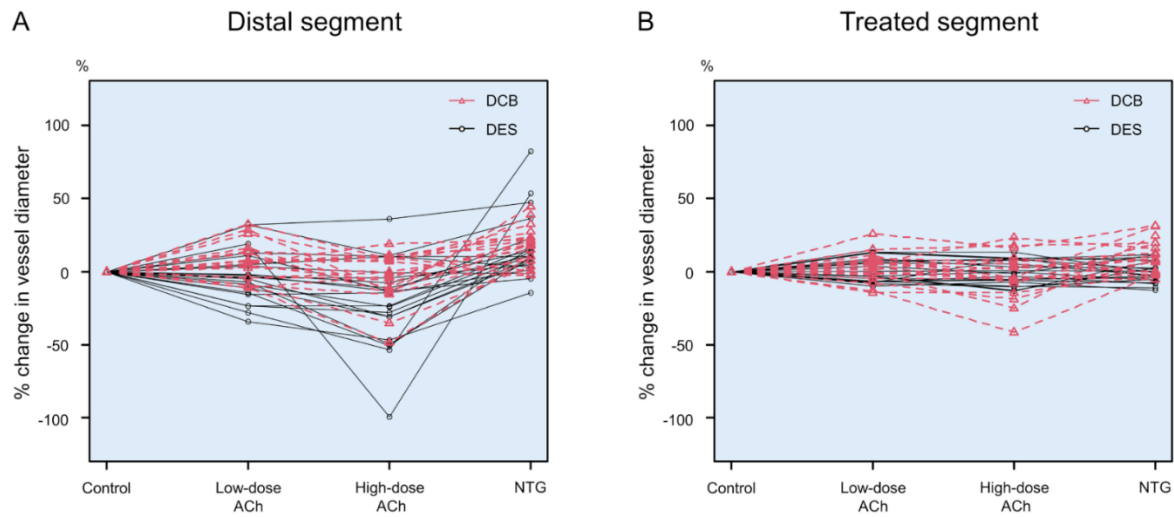
Supplementary data

Supplementary Table 1. Serial changes of IVUS measurements in treated segments.

	DCB n=17	DES n=17	<i>p</i> -value
Pre-procedure			
Mean vessel area, mm ²	8.36 ± 2.72	6.32 ± 1.35	0.009
Mean plaque area, mm ²	4.44 ± 1.76	3.20 ± 0.85	0.014
Mean lumen area, mm ²	3.89 ± 1.28	3.11 ± 0.95	0.052
Minimal lumen area, mm ²	1.51 ± 0.57	1.19 ± 0.22	0.040
Post-procedure			
Mean vessel area, mm ²	9.26 ± 2.94	7.76 ± 1.41	0.066
Mean plaque area, mm ²	4.44 ± 1.73	3.13 ± 0.77	0.008
Mean lumen area, mm ²	4.80 ± 1.42	4.62 ± 0.84	0.647
Minimal lumen area, mm ²	3.48 ± 1.11	3.86 ± 0.86	0.274
Acute gain in minimal lumen area, mm ²	1.97 ± 1.04	2.67 ± 0.79	0.035
Follow-up			
Mean vessel area, mm ²	9.63 ± 3.27	7.91 ± 1.61	0.067
Mean plaque area, mm ²	4.37 ± 1.78	3.86 ± 0.81	0.308
Mean lumen area, mm ²	5.23 ± 1.71	4.04 ± 0.96	0.020
Minimal lumen area, mm ²	3.63 ± 1.57	3.22 ± 0.82	0.346
Late loss in minimal lumen area, mm ²	-0.16 ± 0.88	0.63 ± 0.50	0.003

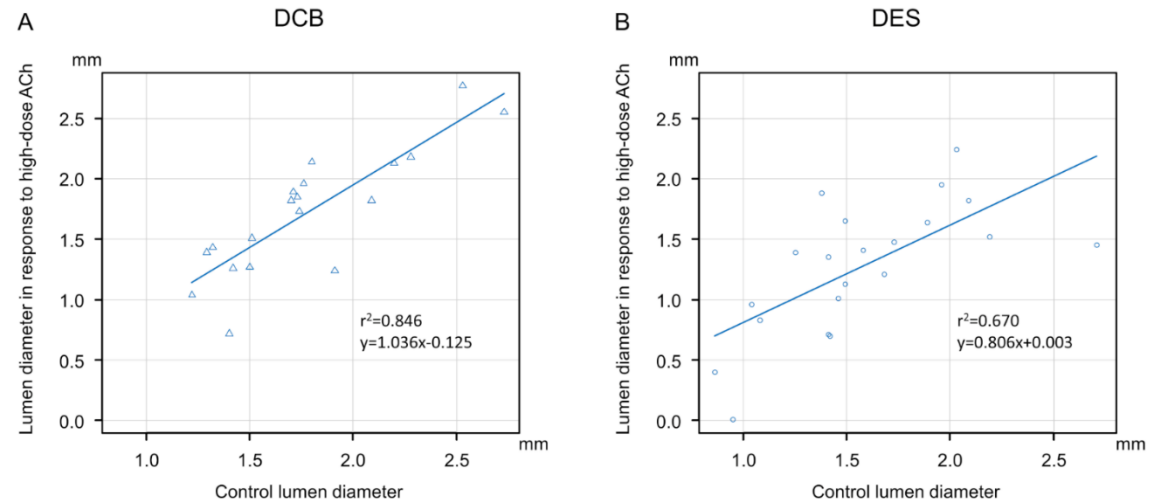
Values are mean±SD.

DCB: drug-coated balloon; DES: drug-eluting stent



Supplementary Figure 1. Percentage changes in lumen diameter in individual cases.

ACh: acetylcholine; DCB: drug-coated balloon; DES: drug-eluting stent; NTG: nitroglycerine



Supplementary Figure 2. Scatter plots and best fit lines of linear regression comparing the control mean lumen diameter and the mean lumen diameter following high-dose ACh infusion in the distal segment. The coefficient of determination is r^2 . The plain line represents the linear regression line expressed by the shown equation.

ACh: acetylcholine; DCB: drug-coated balloon; DES: drug-eluting stent